

**Arterial Lower Limb Duplex**Examined **10/01/2019 11:20**

Page 1 of 2

Gareth Harrison

Reference

Accession **CR-19-0001746**Patient **David Knapp**
D.O.B. **19/06/1946**NHS No **404 527 6394**
Patient Ref **5518966**

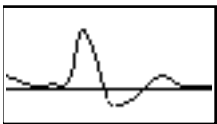
Reason Claudication

Outcome Occlusion

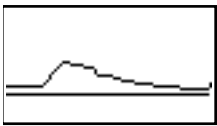
Right

126

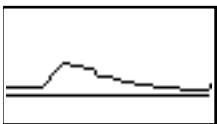
1.00




Good



Weak



Weak



Weak

90

0.71

Brachial**Common Femoral****High Thigh****Low Thigh****Popliteal****High Calf****Peroneal****Anterior Tibial****Posterior Tibial****Dorsalis Pedis****Toe Pressure****Post Exercise****Left**

Good

Absent

Weak

60

0.48

Weak

Notes

BILATERAL LOWER LIMB ARTERIAL DUPLEX:

*No images available on PACS

CFA, PFA origin - widely patent with mild disease, triphasic waveforms, PSV 114-108cm/s.

SFA - proximal to mid vessel appears patent with mild disease, triphasic to monophasic waveforms, PSV 92-58cm/s. Vessel occludes in the very distal thigh to the mid popliteal artery with mixed echogenic material.

Assessed by **Sharifa Kiyegga**

Printed on 30/01/2019 at 4:05 pm

Checked by _____

**Gareth Harrison**

Reference

Accession **CR-19-0001746**

Patient **David Knapp**
D.O.B. **19/06/1946**

NHS No **404 527 6394**
Patient Ref **5518966**

Pop A - proximal vessel is occluded. Mid to distal vessel is patent with weak monophasic waveforms, PSV 12cm/s.

TPT is patent. 2 run-off origins noted.

ATA - poorly viewed but appears patent proximally. Mid vessel appears occluded and vessel appears to reform distally, reduced/ weak monophasic waveforms at the ankle, PSV 22cm/s.

PTA - patent along length, weak monophasic waveforms at the ankle, PSV 17cm/s.

LEFT:

CFA - widely patent with mild disease, triphasic waveforms, PSV 91cm/s.

SFA - proximal to mid vessel appears patent with mild disease, triphasic to monophasic waveforms, PSV 92-58cm/s. Vessel occludes in the very distal thigh to the TPT with mixed echogenic material.

Pop A - occluded

TPT - appears occluded

ATA - patent along length, weak monophasic waveforms at the ankle, PSV 15cm/s.

PTA - appears occluded proximally. mid to distal vessel is patent, weak monophasic waveforms at the ankle, PSV 17cm/s.

Right resting ABPI's reduced (0.71)

Left resting ABPI is severely reduced (0.48).

